



PATIENT

Spike Schippellite

SPECIES

Feline

BREED

DMH

SEX

Male Neutered

AGE

12 years

WEIGHT

9.06lbs

INTERPRETED BY

Maggie Machen
Lamy, DVM
DACVIM (Cardiology)

IMAGING PERFORMED BY

Pamela Harrigan,
RDCS

HOSPITAL NAME

Mass Veterinary Services

REFERRING VET

Dr. Masloski

INVOICE

24650

DATE

6/8/22

PRESENTING CLINICAL SIGNS

History: Spike was noted to have a heart murmur in April. He has an oral mass that needs to be addressed surgically. History FIV positive; history right rear limb amputation secondary to non-healing wound. Thyroid level normal. Good appetite. On exam: NSR, grade III/VI parasternal murmur, PSS, lung fields harsh on inspiration, compressible thorax. BP: 110mmHg x 5. No medications. *No sedation for study.

ECHOCARDIOGRAM FINDINGS

2D, m-mode, color flow and Doppler imaging is available.

Left ventricle: The LV diameter is normal with adequate myocardial function. The LV wall thicknesses are mild to moderately increased with regions of thinning. The papillary muscles are remodeled. The endocardium appears mildly remodeled and fibrotic.

Left atrium: The left atrium is moderately dilated with a horizontal component. The auricle appears dilated as well. No smoke or thrombi seen.

Mitral valve: The anterior leaflet of the mitral valve is mildly elongated, however normal thickness. Systolic anterior motion is seen on 2D imaging. Moderate eccentric MR.

Aortic valve/Aorta: The aortic valve is normal in morphology and mobility. Mildly increased aortic outflow velocity with a dynamic profile. No aortic insufficiency.

Right ventricle: Normal right ventricular diameter and morphology indicating no overt evidence of pulmonary arterial hypertension.

Right atrium: Mild right atrium enlargement.

Tricuspid valve: The tricuspid valve appears normal with no tricuspid regurgitation.

Pulmonary valve/Pulmonary artery: The pulmonic valve is normal in morphology and mobility. No pulmonic insufficiency. Normal RVOT velocity; laminar flow.

Pericardium/other: No pericardial or pleural effusion noted. No obvious cardiac masses.

Heart rhythm: ECG reveals a sinus rhythm with an average HR of 150bpm.

2-Dimensional Measurements

Ao diam (cm)	1.0
LA diam (cm)	1.7
LA:Ao (Swe)	1.7
IVS thickness (cm)	0.68
LVID diastole (cm)	1.28
PW thickness (cm)	0.69
LVID systole (cm)	0.62
FS (%)	50

Doppler Measurements

PV Vmax (m/s)	0.76
AoV Vmax (m/s)	2.3
MR Vmax (m/s)	NA
TR Vmax (m/s)	NA
TR PG (mmHg)	NA

INTERPRETATION OF THE FINDINGS

The diagnosis is hypertrophic obstructive cardiomyopathy. This indicates some degree of LV thickening (moderate in this case) with a dynamic LVOT obstruction (SAM). There is moderate left atrial dilation, indicating the risk for progression to spontaneous CHF and/or a thrombotic event is currently low but risk for progression is high. The right atrium is also mildly enlarged, which is of unknown significance. No additional issues are identified.

Atenolol is certainly recommended in this case to decrease the outflow obstruction (particularly in times of activity). Plavix could also be argued given atrial dilation; however, it can be difficult to administer. Discussion with the owner is advised. No additional cardiac medications are indicated at this time.



PATIENT
Spike Schippelite

Prognosis is guarded yet highly variable given the unpredictable nature of sub-clinical feline cardiomyopathy.

SPECIES
Feline

BREED
DMH

SEX
Male Neutered

AGE
12 years

WEIGHT
9.06lbs

INTERPRETED BY
Maggie Machen Lamy, DVM
DACVIM (Cardiology)

IMAGING PERFORMED BY
Pamela Harrigan, RDCS

HOSPITAL NAME
Mass Veterinary Services

REFERRING VET
Dr. Masloski

INVOICE
24650

DATE
6/8/22

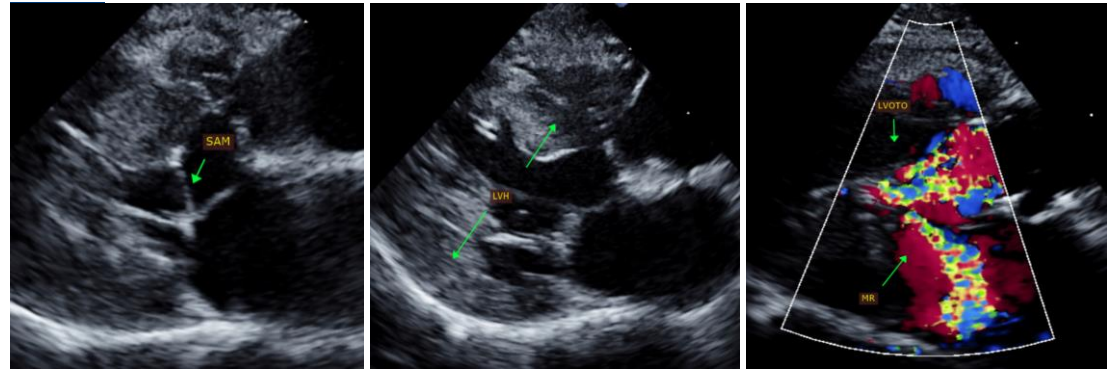
RECOMMENDATIONS

- Administer titrating dose of atenolol: 25mg tablets; Give ¼ tab once daily. Recheck heart rate in 1-2 weeks with target stressed rate of 140-160bpm 12-24 hours post-administration. Increase as needed until target reached.
- Consider addition of Plavix/Clopidogrel 75mg tabs; Give ¼ tab by mouth every 24 hours (NOTE: bitter along cut edge, may cause foaming at the mouth; coat in entirety).
- Screening BP/T4 every 6 months.
- Anesthetic risk is considered elevated, with high risk for fluid overload, spontaneous CHF, hypotension, etc. Judicious IV fluid rates are advised to avoid fluid overload. Drugs that stimulate heart rate should be avoided unless clinically necessary (glycopyrrolate, atropine). Avoid ketamine, telazol, acepromazine and Dexdomitor.
- Monitor for any clinical evidence of cardiac compromise, including respiratory changes and/or signs of a blood clot event (paralysis, neurologic changes, etc.).

PLAN

- Recommend recheck echocardiogram in 6 months to assess rate of progression, sooner if any issues arise in the interim.

IMAGES



The information and recommendations provided are based on the images presented by the referring veterinarian. No evaluation can be communicated regarding pathology that was not visible in the image/video clips provided.

Thank you for this referral. This report was generated using transcription software, and minor dictation errors may be present. If the clinical or image interpretation does not parallel your findings or if I can be of any further assistance, please contact me.

Maggie Machen Lamy, DVM
Diplomate of the American College of Veterinary Internal Medicine (Cardiology)
info@sonopath.com

Echocardiogram performed by: Pamela Harrigan, RDCS
Pet Animal Ultrasound Service (4paus.com)